


Experimental induction of local inflammation in a porcine model of chronic thromboembolic disease

Simone Juel Dragsbæk^{1,2}, Andreas Overgaard^{1,2}, Christina Carøe Ejlskov Pedersen³, Anushree Burade^{4,5}, Mannudeep Kalra^{4,5}, Julie Nelly Christensen⁶, Bettina Hansen⁶, Joanna Kalucka⁶, Mads Dam Lyhne^{7,2} and Asger Andersen^{1,2}

Affiliations: ¹Dept. of Cardiology, Aarhus University Hospital, Denmark; ²Dept. of Clinical Medicine, Aarhus University, Denmark; ³Dept. of Forensic Medicine, Aarhus University, Aarhus, Denmark; ⁴Dept. of Radiology, Harvard Medical School, USA; ⁵MGH Imaging's Division of Thoracic Imaging, Massachusetts General Hospital, USA; ⁶Dept. of Biomedicine, Aarhus University, Denmark; ⁷Dept. of Anesthesiology and Intensive Care, Aarhus University Hospital, Denmark

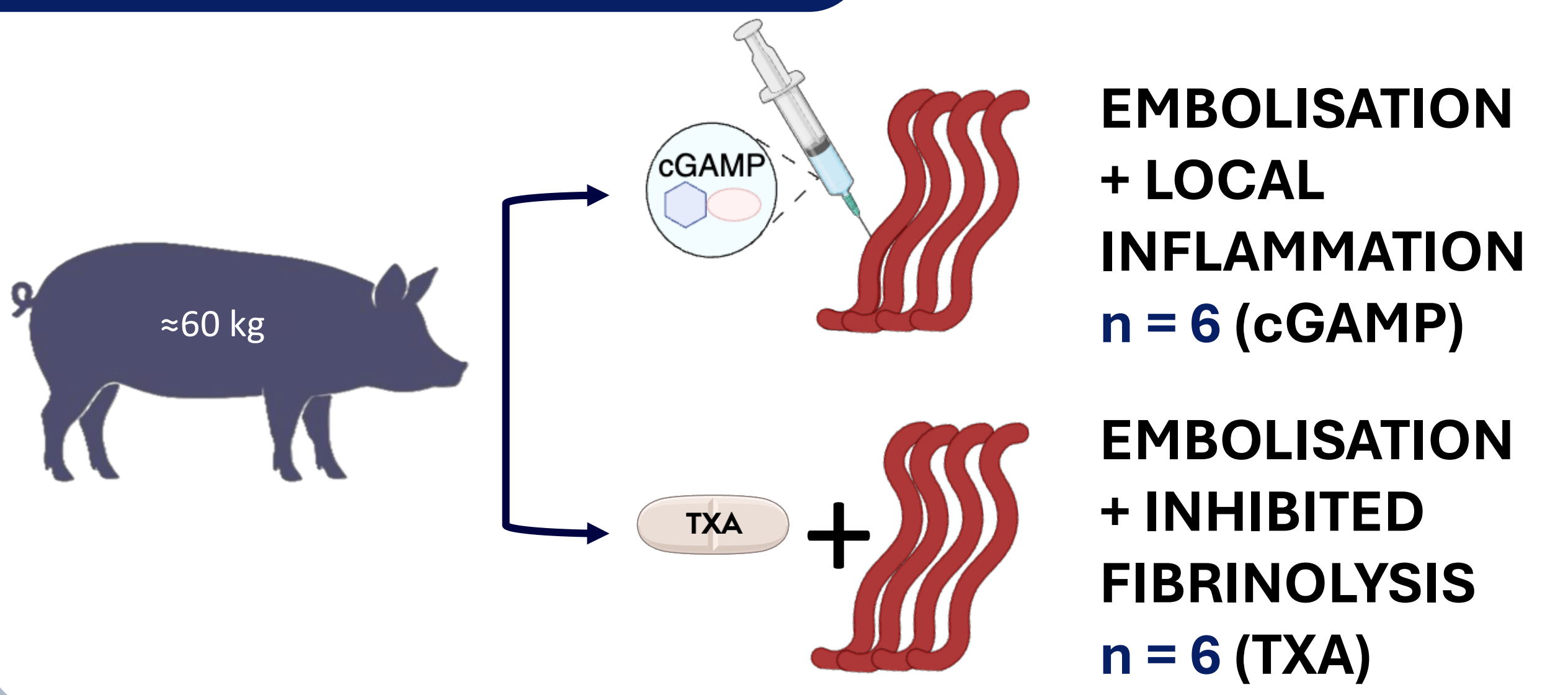
1. BACKGROUND



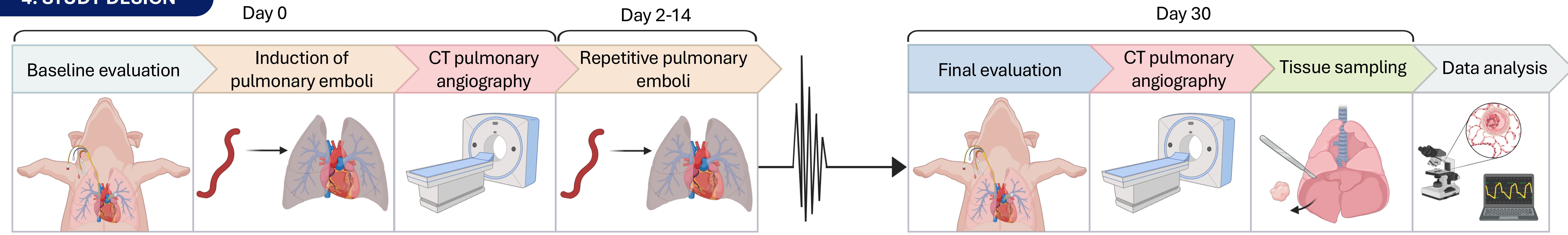
2. AIM

To assess if induction of **local inflammation** influences the long-term **haemodynamic** and **histopathological** outcomes after **repetitive pulmonary emboli** in a porcine model

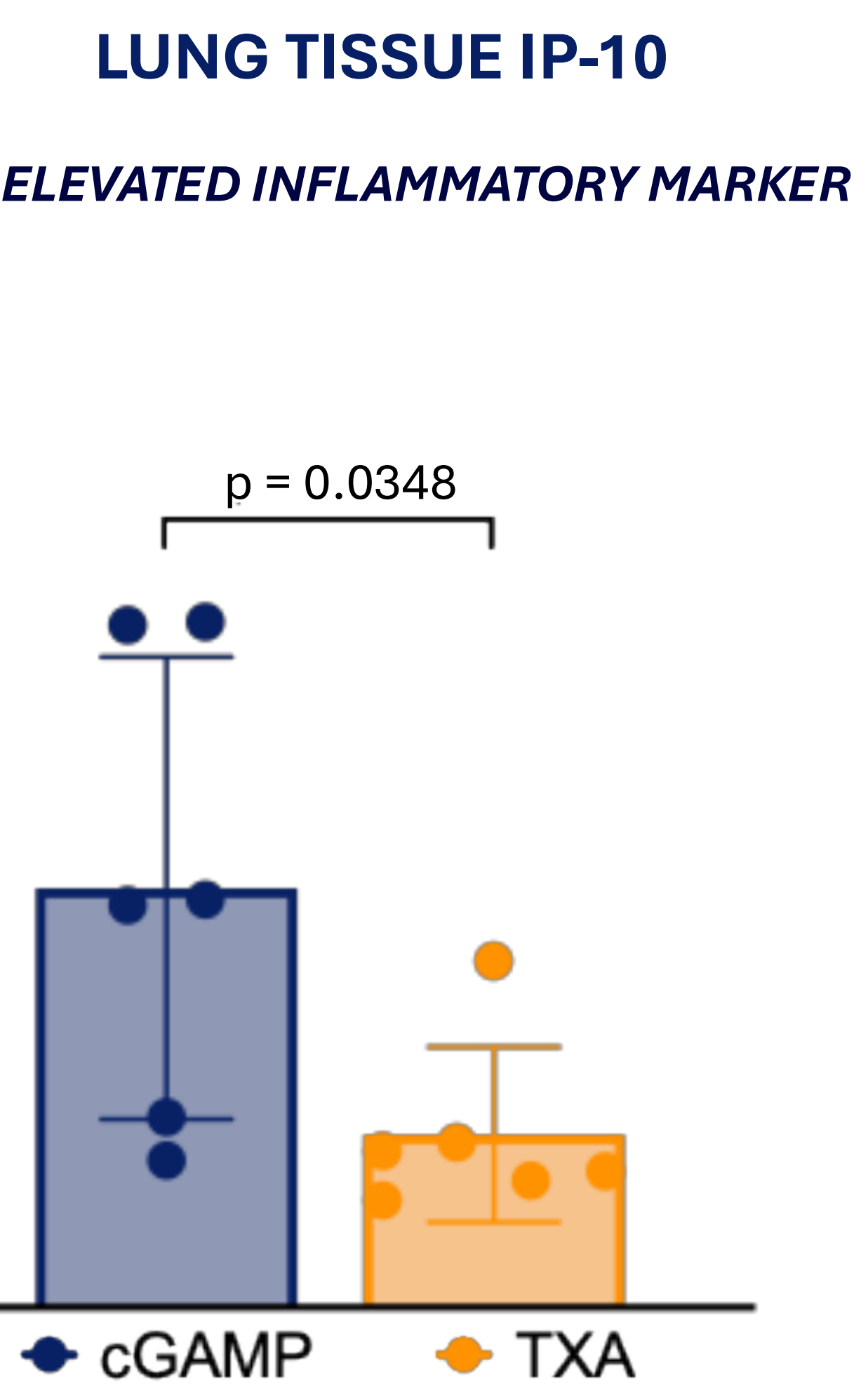
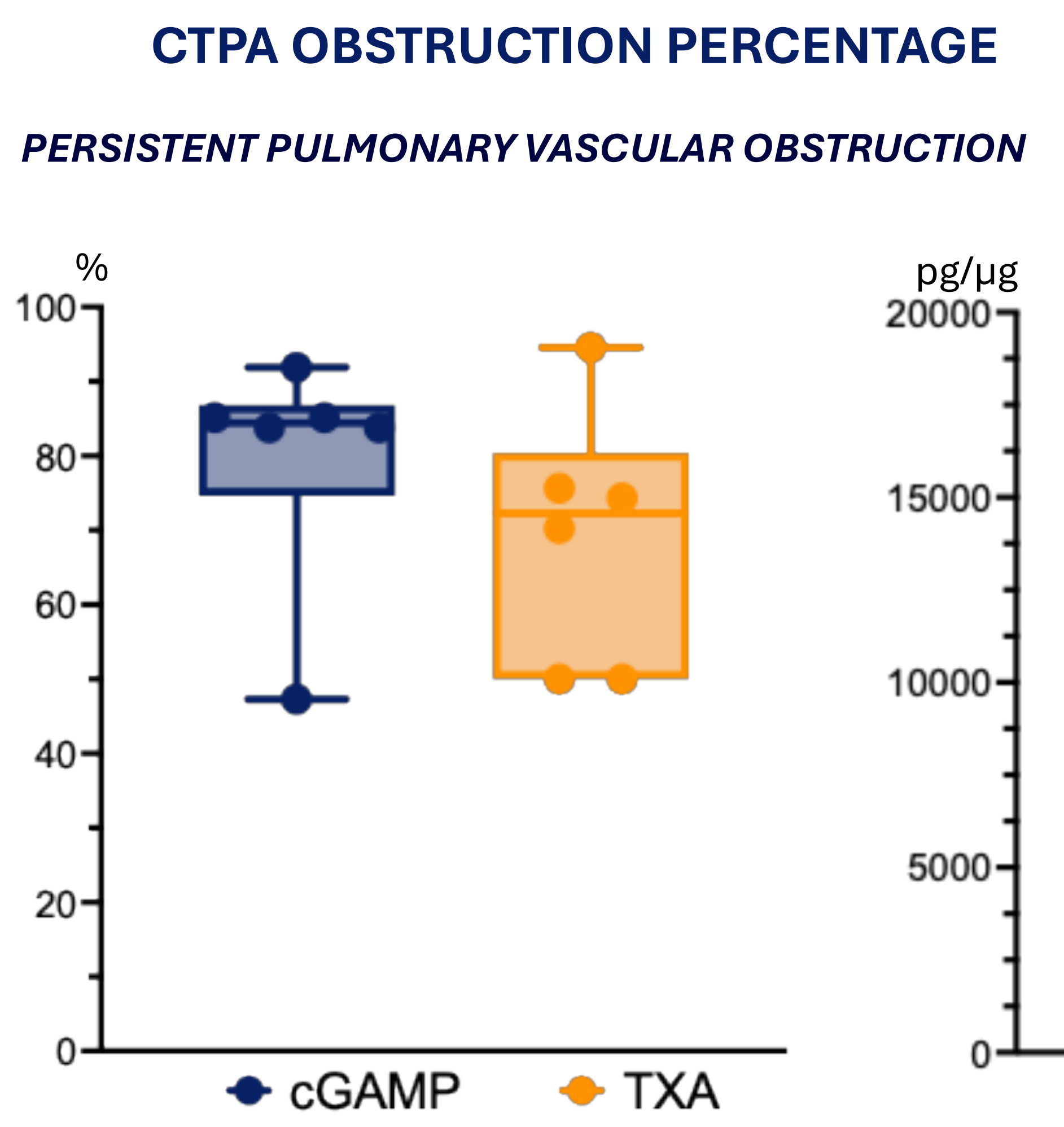
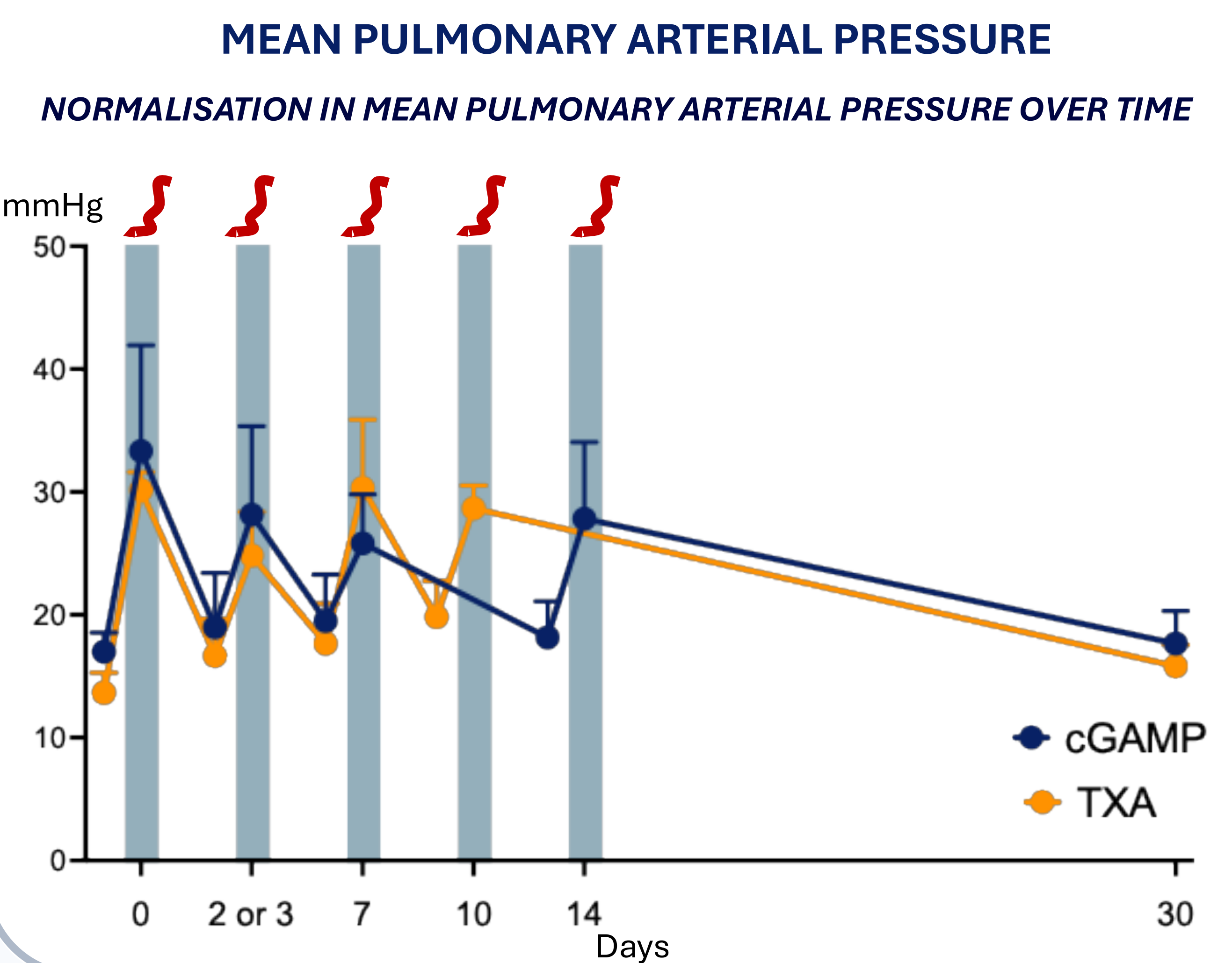
3. EXPERIMENTAL GROUPS



4. STUDY DESIGN



5. RESULTS



TXA GROUP

cGAMP GROUP

Upper panel (left): TXA group. A+D arrowhead shows multinnucleated cells and arrow recanalisation. B. Red arrow mark neointima formation. E. CD3+ cells. C+F. IP-10 positive marker.

Lower panel (left): cGAMP group. G+J arrowhead shows multinnucleated cells and arrow recanalisation. H. Red arrow mark neointima formation. K. CD3+ cells. I+L. IP-10 positive marker.

Upper panel (right): autologous emboli. **Lower panel (right):** Resected lung at follow-up with organised thromboembolic material from cGAMP group.

6. CONCLUSION

Local inflammatory activation increased inflammatory marker **IP-10**

Sustained pulmonary hypertension did not develop despite **persistant organised thromboembolic lesions**

