

International CTEPH Conference 2026

11-13 JUNE 2026
WARSAW, POLAND

ICA International
CTEPH
Association

ICC 2026
Abstract template

Multimodal treatment for CTEPH: early experience in an emerging south-Brazilian centre

- LORENZI William, Thoracic Surgery Service, Hospital de Clínicas de Porto Alegre (HCPA), Porto Alegre-Brazil
- GAZZANA Marcelo Basso, Pulmonology Service, HCPA, Porto Alegre-Brazil
- WAINSTEIN Rodrigo, Cardiology Service, HCPA, Porto Alegre-Brazil
- ARAÚJO Luiz Felipe Lopes, Thoracic Surgery Service, HCPA, Porto Alegre-Brazil
- VALLE Felipe Homem, Cardiology Service, HCPA, Porto Alegre-Brazil
- GUIMARÃES Amanda Reis, Pulmonology Service, HCPA, Porto Alegre-Brazil
- BENEDETTO Igor Gorski, Pulmonology Service, HCPA, Porto Alegre-Brazil



- Mechanical treatments must be offered to all patients with CTEPH.
- Pulmonary endarterectomy (PEA) is the best approach to proximal disease.
- However, patients with PVR >1000-1200 dyn.sec.cm⁻⁵ have a higher mortality¹.
- Also, some patients have very heterogeneous disease, meaning that only one side is amenable to surgery, while the other side could be treated by balloon pulmonary angioplasty (BPA)².
- Combining target drugs, BPA and PEA may be a safer choice for these high surgical risk with or without heterogeneous disease patients.
- Our objective is to present the initial experience of our recently established PEA group with patients submitted to multimodal approaches.

1. Humbert, Eur Respir J, 2023;
2. Jevnikar, Eur Respir J, 2023.



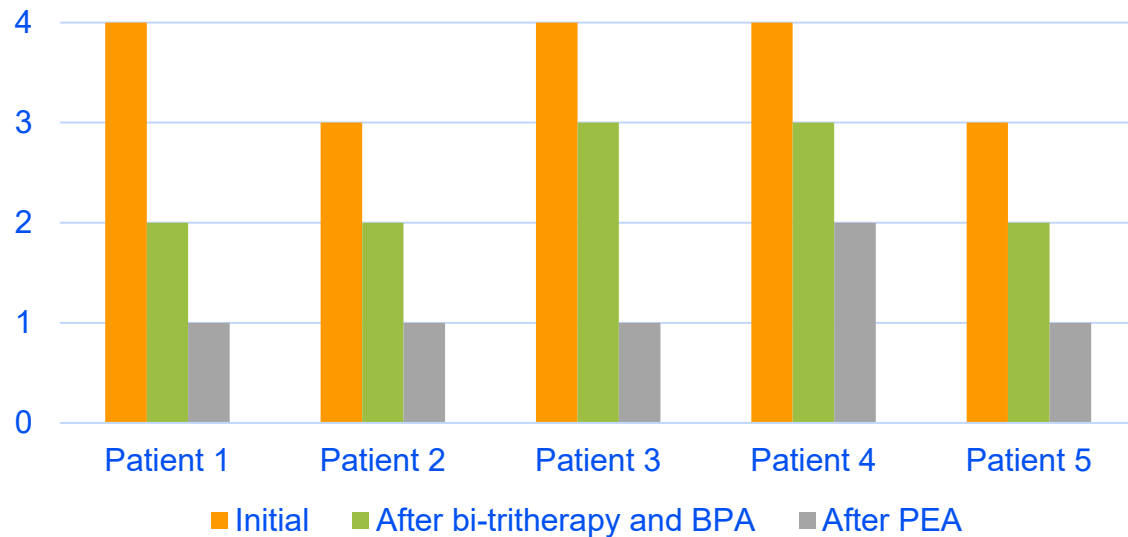
- A multidisciplinary CTEPH team was assembled in our institution in January 2023.
- All patients forwarded to our centre had the diagnosis of CTEPH confirmed by V/Q scintigraphy, pulmonary angioCT and right heart catheterization (RHC).
 - Surgical candidacy evaluation involved routine transthoracic echocardiogram (TTE), cardiac MRI, 6-minute walk test, complete pulmonary function tests, WHO functional class assessment and coronarography (if >40 years old)
- Two sets of patients were selected for multimodal treatment.
 - Mixed lesions, i.e., surgically accessible disease only on one side
 - High surgical risk due to decompensated right heart failure and $PVR > 1000 \text{ dyn}\cdot\text{sec}\cdot\text{cm}^{-5}$
- RHC and TTE were repeated after drug adjustments and BPA sessions, before PEA, whenever feasible.
- PEA was performed under deep hypothermic circulatory arrest (DHCA) at 18°C .



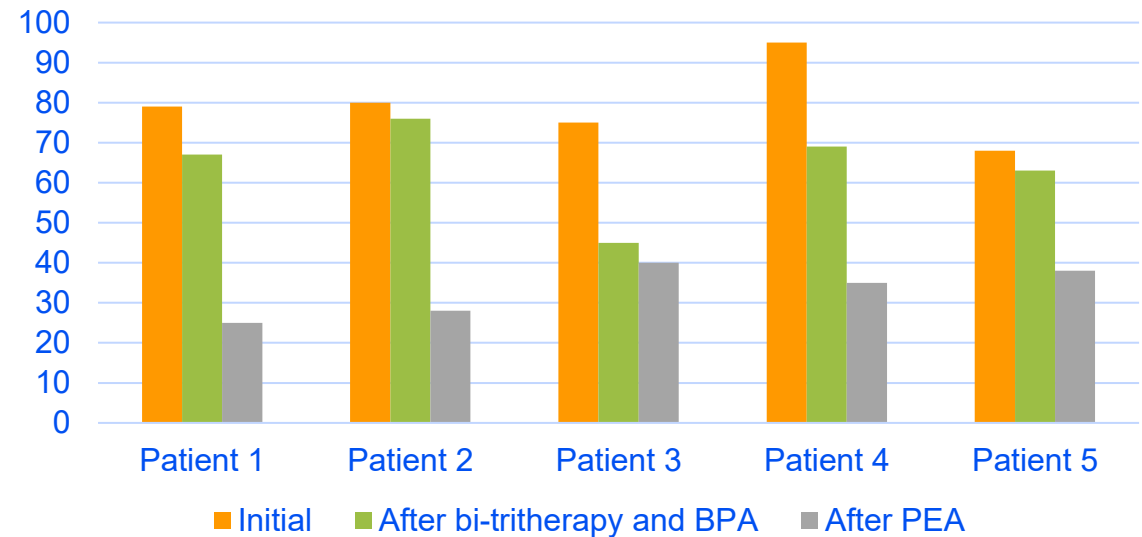
- From March 2023 to February 2026, we performed 37 PEAs at our PH centre.
 - 2 were deemed surgically accessible only on one side
 - 3 had an unacceptably high surgical risk (of which 2 fulfilled the first criterium too)
- For unilateral cases (n=4, all on the right), there was a reduction in aortic cross-clamp time (74min vs 90min) and total DHCA (28min vs 34min).
- As for the lone bilateral case, a flail tricuspid valve correction was also needed. CPB time and aortic cross-clamp times were longer than average (293min vs 265min and 107min vs 90min); total DHCA time was 26min.
- We did not observe any significant complications after either BPA or PEA.
- Mortality was zero among these patients.



WHO Functional Class



TTE estimated PA systolic pressure



- 1: riociguat+sildenafil, left BPA, right PEA
- 2: riociguat+bosentan, left BPA, right PEA
- 3: riociguat+bosentan+sildenafil, left BPA, right PEA
- 4: sildenafil+bosentan+iloprost, bilateral BPA, bilateral PEA
- 5: riociguat+iloprost, left BPA, right PEA



- PEA remains the cornerstone of treatment for CTEPH¹.
- BPA has emerged as an alternative for inoperable cases¹.
- Multimodal treatments challenge traditional concepts in the field, such as no medication before PEA, mandatory bilateral surgical approach and a more difficult surgery after BPA; these concerns have not been confirmed in recent studies.
- Most centres now operate on medically treated patients without any reported decrement in results: pre-PEA drug treatment is safe².
- The French group has published (and updated) a continuously growing series of unilateral PEA after contralateral BPA, with pre-PEA reduction of risk factors³.
- Small reports⁴ such as ours indicate that BPA treated branches can be regularly approached by surgery.

1. Humbert, Eur Respir J, 2023;

2. Fernandes, J Bras Pneumol, 2023.

3. Jevnikar, Eur Respir J, 2023;

4. Shimahara, Interdiscip Cardiovasc Thorac Surg, 2023.



Conclusion

- Starting a PEA program in a developing country is a very challenging task.
- Surgical risk reduction and proper selection of cases is of utmost importance.
- Optimization of target drug therapy and BPA can reduce the surgical risk.
- Unilateral PEA has shorter aortic cross-clamp and DHCA times.
- Endarterectomy of branches previously treated with BPA does not seem to be a technical issue.
- Low-volume centres should be liberal in using multimodal treatments as a tool to mitigate surgical risk, allowing severely ill patients to be operated too.

